

Analysis of Parameters for CVD Risk Using Non-Invasive Methods

¹Harsha Akash Tanti, ²Kumar Saurav, ³Prateek Pushp, ^{*4}Prof. Nishikant Surwade, ⁵Prof. Bahubali Shiragapur

¹⁻⁵ Dr. D. Y. Patil School of Engineering, Lohegaon, Pune, India

*Email: nishikant.surwade@dypic.in

Received: 17th January 2019, Accepted: 13th February 2019, Published: 30th June 2019

Abstract

The eye is considered to be a transparent medium for judging various diseases and mainly problems incurred inside the heart. The eye anatomy is such that it responds to most of the heart problems and hence makes a suitable option for using it for screening. The screening hence decided was just the non-invasive way of analysing the parameters which included cholesterol level, age, gender, smoking status, BMI status, glucose level etc.

For the screening, the image of the retina and iris of patient under test will be taken and passed to processing units. Eye's image so processed is resulted for three major parameters including cholesterol level, age and glucose level respectively. The numbers of parameters extracting from eyes will be increased only to improve accuracy of this screening. The whole analysis can be carried out by any person would be able to keep an eye on cardiovascular health.

Keywords

CVD (Cardio Vascular Diseases), Arcus Senilis.

Introduction

The cardiovascular system consists of the blood (approximately 5 litres), blood vessels and heart. It is also responsible for transportation of nutrients, cellular waste products, oxygen and hormones throughout the body.

The heart powers the cardiovascular system which makes it the body's hardest-working organ. Even at rest, the average heart easily pumps over 5 litres of blood throughout the body every minute [1].

Any diseases which involve the heart or blood vessels can be considered as cardiovascular disease (CVD).

CVDs include various diseases, to mention a few, they are- angina, myocardial infarction (commonly known as a heart attack), stroke, heart failure, hypertensive heart disease, cardiomyopathy, aortic aneurysms, congenital heart disease, rheumatic heart disease, heart arrhythmia, valvular heart disease, peripheral artery disease, carditis, thromboembolic disease and venous thrombosis.

Cardiovascular disease can be of many types and some of the famous types are mentioned below-

Arrhythmia-

Arrhythmia is an irregular heartbeat. The heartbeat can lose its regular rhythm in different ways. These include:

- Premature ventricular contractions, or additional, abnormal beats
- Bradycardia, the heart beats too slowly
- Fibrillation, the heartbeat is irregular
- Tachycardia, the heart beats too fast

Arrhythmias occur when heartbeat do not work correctly which is coordinated by the electrical impulses in the heart. These make the heart change its rhythm in a way it shouldn't, it could be too fast, slow or erratically.

However, when they occur too frequently because of damaged or weak heart, they can be considered more dangerous and need to be treated as soon as possible.

Coronary Artery Disease-

The main function of these arteries is to supply required nutrients and oxygen to heart via blood. Cholesterol containing plaque deposits can be found at the edges of coronary arteries making it infected and damaged. This plaque generation at the edges of arteries blocks the path of blood which carries required nutrients for heart.

Dilated Cardiomyopathy-

The heart chambers becomes somewhat enlarged, so as a result muscle of heart walls weakens and thus can't pump the blood properly. Commonly known reason is lack of oxygen reaching the heart muscle, due to coronary artery disease. This generally affects the place where oxygenated blood enters (left ventricle).

Myocardial Infarction-

It is generally known as heart attack or cardiac infarction or coronary thrombosis. An obstruction to blood flow may very well damage or destroy part of the heart muscle. A blood clot can develop in one of the coronary arteries resulting heart attack or it can also occur if an artery suddenly and involuntarily contracts.

Heart Failure-

Better known as congestive heart failure, occurs when the heart does not pump blood around the body as required. This results from the various heart diseases like coronary heart disease, Cardiomyopathy and so on and affects majorly one side of heart that is left side or right side of heart.

Hypertrophic Cardiomyopathy-

It is a genetic disorder where the walls of the left ventricle thicken which makes it harder for blood to be pumped out from the heart. This is the major cause of sudden death in athletes. There is a 50 per-cent chance of passing Hypertrophic Cardiomyopathy as a disorder to the offspring of the person i.e. on to their children.

Mitral Regurgitation-

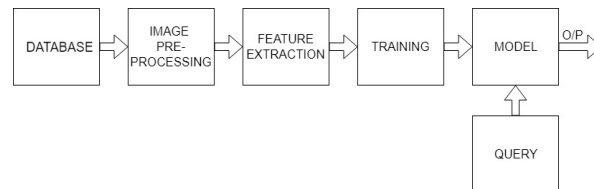
Also known as mitral insufficiency, mitral valve regurgitation, or mitral incompetence, it occurs when the closing of the mitral valve in heart is not tight enough. This sometimes allows blood to flow back into the heart instead of leaving. As a result, there is no efficient movement of blood through the heart or body. People with this heart condition as a result often feel tired and out of breath.

It is estimated that major portion of CVD is preventable. Prevention includes practicing regular exercise, limiting alcohol intake, forging tobacco, smoking and so on. Treating risk factors is also a beneficial approach.

Cardiovascular diseases are one of the leading causes of death globally. This is true in all areas of the world except Africa as there the leading causes are viral, bacterial or parasitic infections. Out of 100%, 32.1% of deaths in 2015 amounting 17.9 million people and 25.8% of deaths in 1990 amounting 12.3 million people were caused by CVDs. Deaths, at a given age, from CVD are increasing at a alarming rate and are becoming in the developing world, while rates have declined in most of the developed countries since the 1970s but the Coronary artery disease and heart stroke account for 80% of deaths in males and 75% of deaths in females.

Methodology

Cardiovascular disease manifests itself in the retina in a number of ways. Atherosclerosis and Hypertension cause the change in the ratio between diameter of retinal arteries and veins also known as A/V ratio. A decrease in the A/V ratio, i.e., thinning of the arteries and widening of the veins, is associated with an increased risk of stroke and myocardial infarction. Hypertension can also cause direct retinal ischemia, which causes dead tissue on retina which is visible as cotton wool spots as well as dead tissue on choroid which is visible as deep retinal white spots. In addition, systemic vascular disease can cause arterial and venous occlusions, known as central and branch arterial occlusions (CRAO, BRAO) and central and branch venous occlusions (CRVA, BRVO)[2].



Preprocessing of Retinal Image-

RGB to Gray Image: Original images as shown below. First, the image was converted to gray scale from RGB scale using suitable MATLAB command for the brighter appearance of the optic disc than its background. Proper resizing of image is also done [3].

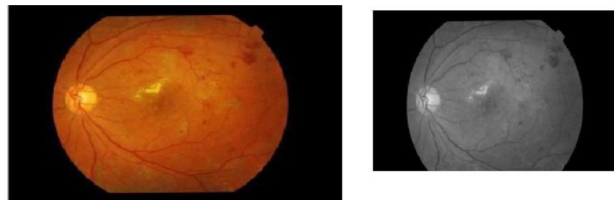


Figure 1: Original Image and Preprocessed Image

Contrast-limited Adaptive Histogram Equalization (CLAHE): This adaptive histogram equalization enhances the contrast of the gray scale image. CLAHE is said to operate under small regions in the tiles of the image. Each tile's contrast is improved, so as the histogram of the output region approximately matches the histogram specified by the Distribution parameter. The contrasts, generally in homogeneous areas, are limited to avoid amplifying any noise that could be present in the image [3].

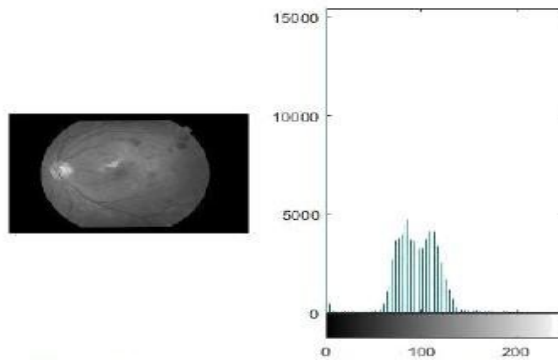


Figure 2: Retinal Image and its Histogram

Binary Thresholding: Converts the grayscale image to binary by thresholding. The output binary image has values of 1 (white) for all pixels in the input image with luminance greater than threshold and 0 (black) for remaining pixels. Proper value of threshold is chosen for training and fixed automatically.

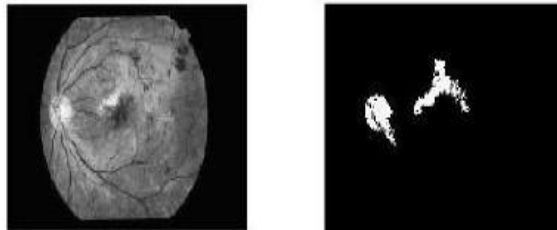


Figure 3: Background Noise Eliminated Image[3]

Mathematical Morphology for Background Noise Elimination: Morphological operation is done to remove the noise present in the background of retinal image. Morphological open is done to remove the blood vessels present whose diameter is smaller compared with OD and smoothed the inner small vessels in the Optic disc region. Opening operation is used to remove noise and CCD defects. Morphologically open binary image (remove small objects) represents the noise elimination of the image.

Algorithms for Various Features-

GENDER(SEX)

- Calculate mean foveal thickness from retinal image
- Check if foveal thickness is (201+-4)cm, which indicates that the person is male.
- Check if foveal thickness is (186+-4)cm, which indicates that the person is female.
- Any other abnormal values may indicate that retina is damaged or person has optic disease[5].

HYPERTENSION

- Using/applying Modified Gaussian Filter (which consists of Gaussian filter and kalman filter) to retinal image, all branches of blood vessel can be extracted.
- Out of all these branches, smaller branches, larger branches, and trunk artery and vein can be separated.
- CRAE , CRVE , AVR can be calculated with following formulae-

$$0.87w_a^2 + 1.01w_b^2 - 0.22w_a w_b - 10.76 = w(crae)$$

$$0.72w_a^2 + 0.91w_b^2 + 450.05 = w(crve)$$

$$\frac{w_{crae}}{w_{crve}} = AVR$$

w_a = width of small branch

w_b = width of larger branch w_{crae} = width of trunk artery

w_{crve} = width of trunk vein

AVR = Arteriolar to Venular ratio

- Mean values and standard Deviation of CRAE are 118.9 μ m and 12.4 μ m for people with hypertension and the same is 122.5 μ m and 12.5 μ m for people without hypertension.
- Mean values and Standard Deviation of CRVE are 168.1 μ m and 18.2 μ m for people with hypertension and the same is 170.3 μ m and 18.5 μ m for people without hypertension[3].

DIABETIC RETINOPATHY

- Hemorrhage and exudates (leakage of yellowish fluid) can be extracted from retinal image by means of RGB to Grey conversion and morphological processing followed by thresholding.
- The amount of Hemorrhage and exudates directly implies to higher diabetes and damage to the eyes[3].

HYPERGLYCEMIA(Glucose level)

- The risk of CVD increases if a person has higher glucose level (Diabetes). The macula(Macula is the central part of retina which is responsible for sharpness of vision) of eyes gets broaden/swollen when a person has higher glucose level.
- By use of edge enhancement and edge detection (EEED) along with LoG and thresholding, macula can be found out.
- The broadening of macula is pre-dominant on people suffering from DME(Diabetic macular edema)[6].

AGE

- Mean foveal thickness and central foveal thickness increases with age.
- This mean foveal thickness and central foveal thickness are directly obtained by using *stratus OCT™* device output[5].

HIGH CHOLESTROL LEVEL

- The segmentation process needs to be done to segment outer boundary and the inner boundary of pupil by searching central point of pupil.
- Image can be cropped based on value of Iris radius.
- Next the image is transformed to normalized polar coordinates using ‘Rubber Model’.
- Lastly, image histogram is plotted to confirm the presence of white ring around iris which is also called *Arcus senillis*[4].

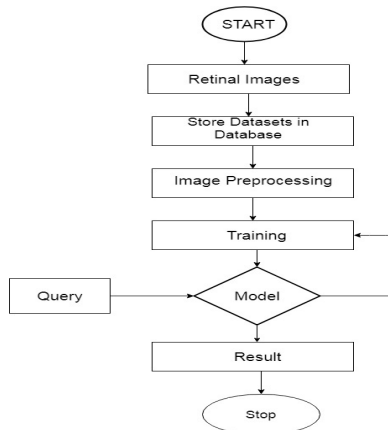


Figure 4: Detection of High Cholesterol

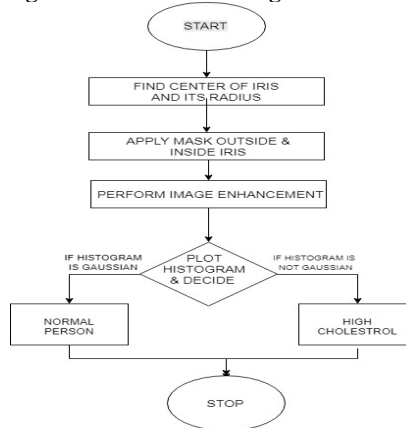


Figure 5: Flowchart for Combined Parameters of CVD Risk.

Results and Discussion
Healthy Eye Image

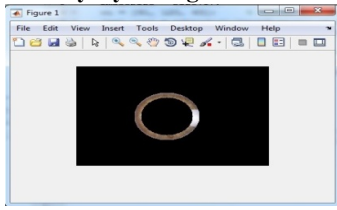


Fig A.1

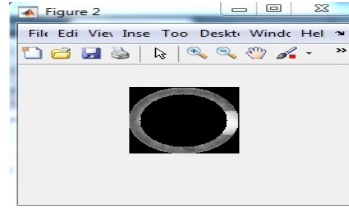


Fig A.2

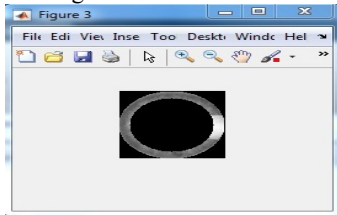


Fig A.3

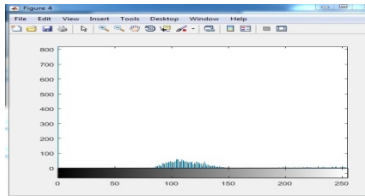


Fig A.4

Arcus Senillis Affected Eye

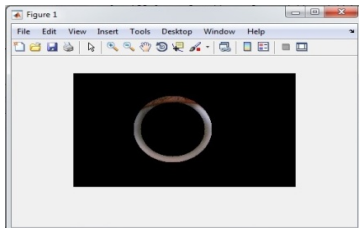


Fig B.1

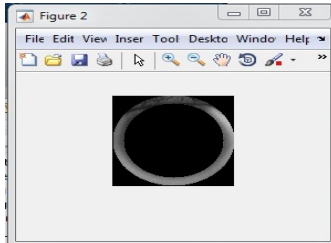


Fig B.2

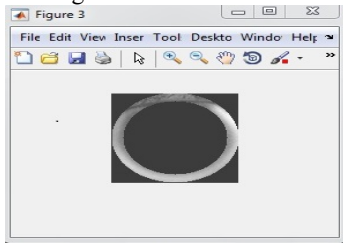


Fig B.3

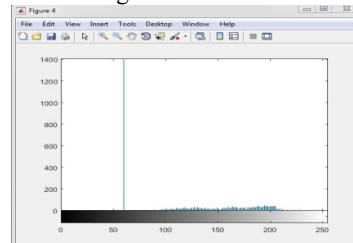


Fig B.4.

In both A and B figure sets, the Figure1 represents masking of concentric circle to separate out iris, then some image enhancement technique is implemented. Figure2 represents conversion of RGB image to grayscale image because histogram plot can only be performed for gray scale image. Figure 3 is passed through contrast stretching so that errors in further processing can be reduced and Figure4 histogram is plotted from contrast stretched.

The result of the graph can be represented as Gaussian curve in the healthy eye image, and if the eye is affected with arcus sinilis then the plotted graph of histogram is spread out.

So, one can distinguish between the healthy eye and arcus sinilis affected eye by seeing the histogram plot which can be used to train different models using AI, Machine learning algorithm to automatically distinguish between the two i.e. healthy eye images from arcus sinilis affected eye.

Conclusion

Through this project, the non-invasive way of analysing the parameters for cardiovascular disease risk was screened in order to bypass the invasive or traditional methods .The idea so suggested not only reduces the tediousness of carrying out the invasive screening but also the scope of improvement is prevailed. The detailed image analysis of eye and its anatomy subjectively supports the facts and figures required to analyse about parameters of cardiovascular disease risk. The cholesterol level, age and hypertension collectively were

prioritized as the quintessential parameter to judge through retina and iris of respective people in order to analyse the CVD risk.

Acknowledgement

This is to acknowledge our guide Prof. Nishikant Surwade under whose guidance, our group was able to move forward in the direction of analysis of parameters for CVD risk using non-invasive method which has effected humans from many centuries.

References

- [1] Hall, John (2011). Guyton and Hall textbook of medical physiology (12th ed.). Philadelphia, Pa.: Saunders/Elsevier. ISBN 978-1-4160-4574-8.
- [2] Carol Y. Cheung, George N. Thomas, Wanting Tay, M. Kamran Ikram, Wynne Hsu, Mong Li Lee, Qiangfeng Peter Lau, And Tien Yin Wong, "Retinal Vascular Fractal Dimension and Its Relationship With Cardiovascular and Ocular Risk Factors", April 24, 2012, 0002-9394 © 2012 ELSEVIER INC. DOI: 10.1016/j.ajo.2012.04.016.
- [3] M. Kamaladevi, S. Sneha Rupa and T. Sowmya, "Automatic Detection of Diabetic Retinopathy in Large Scale Retinal images", International Journal of Pure and Applied Mathematics Volume 119 No. 12 2018, 14181-14189.
- [4] Sarika G. Songire and Madhuri S. Joshi, "Automated Detection of Cholesterol Presence using Iris Recognition Algorithm", International Journal of Computer Applications (0975 – 8887), Volume 133 – No.6, January 2016.
- [5] Amir H. Kashani, Ingrid E. Zimmer-Galler, Syed Mahmood Shah, Laurie Dustin, Diana V. Do, Dean Elliott, Julia A. Haller, and Quan Dong Nguyen, "Retinal Thickness Analysis by Race, Gender, and Age Using Stratus OCT™", Am J Ophthalmol. 2010 March; 149(3): 496–502.e1. doi:10.1016/j.ajo.2009.09.025.
- [6] Dilip Singh Sisodia, Shruti Nair and Pooja Khobragade, "Diabetic Retinal Fundus Images: Preprocessing and Feature Extraction For Early Detection of Diabetic Retinopathy" National Institute of Technology Raipur, India. May 30, 2017, Biomedical & Pharmacology Journal Vol. 10(2), 615-626 (2017).